

RESEARCH

Open Access



Preliminary evaluation of SaCoVLMTM video laryngeal mask airway in airway management for general anesthesia

Chun-ling Yan^{1†}, Ying Chen^{1†}, Pei Sun², Zong-yang Qv¹ and Ming-zhang Zuo^{1*}

Abstract

Background: To preliminary evaluate the application of SaCoVLMTM video laryngeal mask airway in airway management of general anesthesia.

Methods: We recruited 100 adult patients (ages 18–78 years, male 19, female 81, weight 48–90 kg) with normal predicted airway (Mallampati I ~ II, unrestricted mouth opening, normal head and neck mobility) and ASA I–II who required general anaesthesia. The SaCoVLMTM was inserted after anesthesia induction and connected with the anesthesia machine for ventilation. Our primary outcome was glottic visualization grades. Secondary outcomes included seal pressure, success rate of insertion, intraoperative findings (gastric reflux and contraposition), gastric drainage and 24-h complications after operation.

Results: The laryngeal inlet was exposed in all the patients and shown on the video after SaCoVLMTM insertion. The status of glottic visualization was classified: grade 1 in 55 cases, grade 2 in 23 cases, grade 3 in 14 cases and grade 4 in 8 cases. The first-time success rate of SaCoVLMTM insertion was 95% (95% CI = 0.887 to 0.984), and the total success rate was 96% (95% CI = 0.901 to 0.989). The sealing pressure of SaCoVLMTM was 34.1 ± 6.2 cmH₂O and the gastric drainage were smooth. Only a small number of patients developed mild complications after SaCoVLMTM was removed (such as blood stains on SaCoVLMTM and sore throat).

Conclusions: The SaCoVLMTM can visualize partial or whole laryngeal inlets during the surgery, with a high success rate, a high sealing pressure and smooth gastroesophageal drainage. SaCoVLMTM could be a promise new effective supraglottic device to airway management during general anesthesia.

Trial registration: ChiCTR, [ChiCTR2000028802](https://www.chictr.org/record/ChiCTR2000028802). Registered 4 January 2020.

Keywords: Airway management, Glottic exposure classification, General anesthesia, SaCoVLMTM video laryngeal mask, Sealing pressure

Background

Since the introduction of laryngeal mask in the late 1980s, the “blind” insertion technique described by Dr. Brain has been widely used in clinical practice [1]. Preliminary studies found that approximately 40 to 60% of the laryngeal mask inserted with bronchofiberscope, and some even require re-alignment to improve ventilation [2, 3]. In realigning the laryngeal mask, complications, such as

*Correspondence: zuomz@163.com

[†]Chun-ling Yan and Ying Chen contributed equally to this work.

¹ Department of Anesthesia, Beijing Hospital, National Center of Gerontology, Institute of Geriatric Medicine, Chinese Academy of Medical Sciences, Beijing, PR China

Full list of author information is available at the end of the article



© The Author(s) 2021. **Open Access** This article is licensed under a Creative Commons Attribution 4.0 International License, which permits use, sharing, adaptation, distribution and reproduction in any medium or format, as long as you give appropriate credit to the original author(s) and the source, provide a link to the Creative Commons licence, and indicate if changes were made. The images or other third party material in this article are included in the article's Creative Commons licence, unless indicated otherwise in a credit line to the material. If material is not included in the article's Creative Commons licence and your intended use is not permitted by statutory regulation or exceeds the permitted use, you will need to obtain permission directly from the copyright holder. To view a copy of this licence, visit <http://creativecommons.org/licenses/by/4.0/>. The Creative Commons Public Domain Dedication waiver (<http://creativecommons.org/publicdomain/zero/1.0/>) applies to the data made available in this article, unless otherwise stated in a credit line to the data.

hypoxia and laryngeal spasm, might occur [4]. Technical innovation should be made to assure the perfect alignment of laryngeal mask and minimize adverse airway events. SaCoVLM™ video laryngeal mask (SaCoVLM™ ZHEJIANG UE MEDICAL CORP. Add:No.8, Youyi Road, Baita Economic Develop Zone, Xianju, Zhejiang, China) has been recently invented. Using new technology combining camera and Laryngeal mask, it can visualize the conditions around the glottis, thus achieving rapid and accurate insertion. In addition, during the maintenance of anesthesia, the conditions around the glottis could be monitored, through which the position of SaCoVLM™ could be corrected in time to prevent aspiration of perilaryngeal secretions and reduce stimuli to the throat. The purpose of this study was to observe the visibility of SaCoVLM™ video laryngeal mask in clinical use and to preliminarily evaluate its application in airway management under general anesthesia.

Methods

Subjects

This single-center prospective observational study was approved by the Ethics Committee of Clinical Research of Beijing Hospital (No. 2019BJYYEC-236-02) and registered in the China Clinical Trial Registration Center (No. ChiCTR2000028802 Date2020.01.04). Between February 2020 and December 2020, 100 adult patients who received SaCoVLM™ for general anesthesia were recruited and informed consent was obtained. The sample size of 100 cases is based on a similar preliminary evaluation of a new laryngeal mask airway by Liu et al. [5]. Inclusion criteria: age ≥ 18 ; gender unrestricted; ASA I-II; $18 \text{ kg/m}^2 \leq \text{BMI} \leq 30 \text{ kg/m}^2$; Normal airway. Exclusion criteria:

severe respiratory diseases; lateral or prone surgical positions; mouth opening less than 2 cm; edentulous; the presence of risk factors for gastric reflux or aspiration, including fasting, morbid obesity, gestation over 14 weeks, ileus, and hiatal hernia; other laryngeal mask contraindications, included intraoral, laryngeal surgery and thoracic surgery.

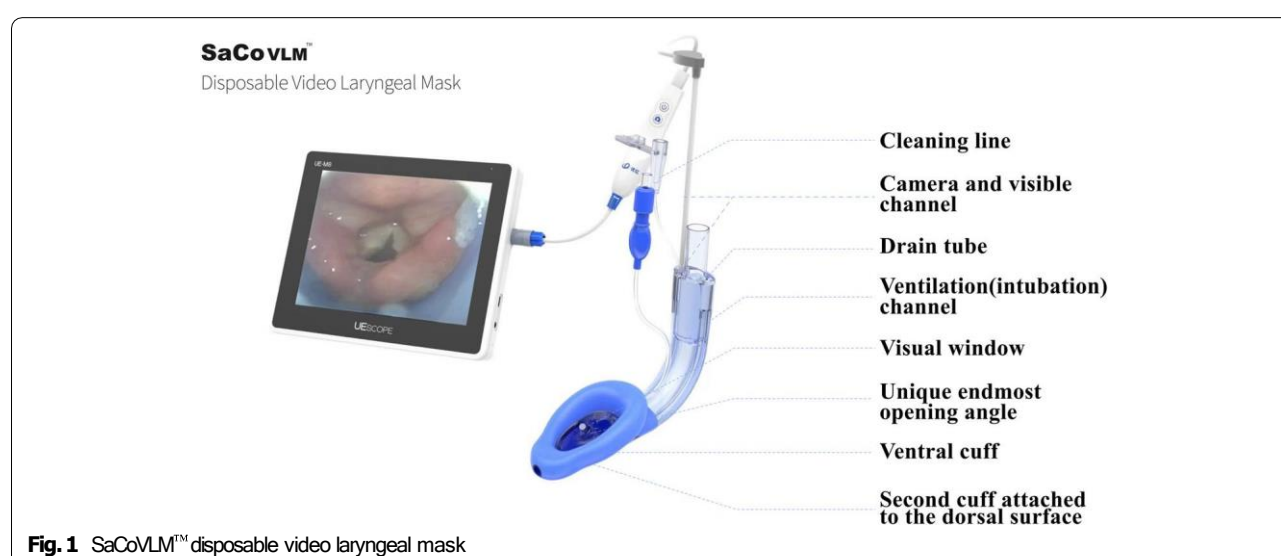
All the methods in this study were performed in accordance with the relevant guidelines and regulations in the Methods section.

Preparation of SaCoVLM™

Disposable SaCoVLM™ (Fig. 1) includes a visual channel, a ventilation (intubation) channel, a gastric tube channel, a camera (electronic camera, focal length 7 mm, field angle $90^\circ \pm 13.5\%$, ZHEJIANG UE MEDICAL CORP.) and connecting wires. The camera is fixed on the right side of ventral cuff, connected with the screen and inserted into the visual channel. During placement, the SaCoVLM™ is adjusted according to the image displayed on the screen. The data are stored in a chip. A rechargeable battery is used to provide energy. The SaCoVLM™ was selected according to the patient's weight. Size 3 was used for patients weighing 30–50 kg, size 4 for patients weighing 50–70 kg, and size 5 for patients weighing 70–90 kg. Before placement, the cuff was deflated and flattened. The back of the laryngeal mask was lubricated with Lidocaine Hydrochloride Gel. The camera was inserted into the visual channel and connected with the screen before later use.

Preoperative preparation

All subjects were forbidden to drink for 6 h and fasted for 8 h before operation. The general information of the



patients was asked before surgery, including age, height and weight. We measured the thyromental distance, the mouth opening of the patients, Mallampati classification, upper lip occlusion test and ASA classification.

Peripheral venous access was initiated in the operating room. Electrocardiogram (ECG), heart rate (HR), blood pressure (BP), oxygen saturation (SpO₂) and bispectral index (BIS) were monitored.

Anesthesia and airway management

The patient was preoxygenated with 100% oxygen (5 L/min, 5 min) before induction using a facemask and the head was placed in the neutral supine position. General anesthesia was induced with sufentanil (0.2–0.5 µg/kg), propofol (2 mg/kg) and cis-atracurium (0.2 mg/kg). The patient's lungs were manually ventilated when the BIS was reduced to below 60. After obtaining easy mask ventilation and a relaxed airway, the SaCoVLM™ was inserted. The anesthetist held the distal end of the ventilation channel and let the laryngeal mask slide down the palatopharyngeal curve along midline in the mouth, until the front end of SaCoVLM™ was inserted into the hypopharyngeal cavity. The SaCoVLM™ was inflated to achieve a maximum cuff pressure of 60 cmH₂O (1 cmH₂O = 0.098 kPa) detected by a hand-held manometer (VBM, German). Artificial ventilation was performed. The glottic visualization was observed and a gastric tube (12Fr) was placed through the gastroesophageal channel. After proper fixation of SaCoVLM™, positive pressure ventilation was performed. Mechanical ventilation parameters were set: tidal volume 6–8 mL/kg, inhalation/exhalation ratio 1:2, ventilation frequency 12 times/min and P_{ET}CO₂ 35–45 mmHg (1 mmHg = 0.133 kPa). Fibre-optic bronchoscopy was performed to grade the glottic exposure. The SaCoVLM™ insertion was considered successful when the following criteria were met: chest movement and no air leakage during normal ventilation; more than two continuous end-expiratory carbon dioxide waveforms; positive suprasternal concave gel test; the gastric tube successfully implanted and the ventilation

channel connected to the anesthesia machine for mechanical ventilation. The criteria of SaCoVLM™ insertion failure: failure to place the SaCoVLM™ correctly after more than 2 times and longer than 60 s; abnormal P_{ET}CO₂ waveforms; bellows collapsing. All procedures were performed by the same anesthesiologist experienced in the use of SaCoVLM™. Time of SaCoVLM™ insertion referred to the time between SaCoVLM™-incisors contact and the first ventilation showing two P_{ET}CO₂ waveforms. If the air leakage was obvious, the position of SaCoVLM™ needed to be adjusted using one or more of the following methods: the up-down maneuver, raising the jaw with both hands, the Chandy maneuver, increasing and reducing the amount of air, reinsertion and changing the size. The position and function of SaCoVLM™ was reevaluated after adjustment. If the insertion failed twice, endotracheal intubation was performed.

The pressure gauge stability method was used to measure the sealing pressure inside the SaCoVLM™ [6]. The fresh gas flow rate was adjusted to 3 L/min, the pressure was adjusted to 40 cmH₂O, and mechanical ventilation was switched to manual ventilation. When the sound of air leakage was heard, the pressure was gauged as the sealing pressure. For the sake of safety, the maximum oropharyngeal leak pressure was set to be 40 cmH₂O.

Anesthesia was maintained with targeted-infusion of propofol (2.5–3.5 µg/ml) and remifentanyl (3–4 ng/ml), punctuated with infusion of cisatracurium. BIS was controlled at 40–60. Propofol and remifentanyl infusion was stopped and muscle relaxation antagonism was performed after the skin was sutured. As the patient awakened and the mouth could open as directed, the SaCoVLM™ was removed. The patient was transferred to the Post Anesthesia Care Unit (PACU).

We divided the glottic exposure into four grades under SaCoVLM™ (Fig. 2). Grade 1: visualization of the lateral part of the right aryepiglottic fold and part of the laryngeal inlet, and the ventilation was good; Grade 2: visualization of the bilateral aryepiglottic fold and part of laryngeal inlet, and the ventilation was good; Grade 3: visualization of all laryngeal inlet and posterior glottis; Grade 4: visualization of the whole glottis

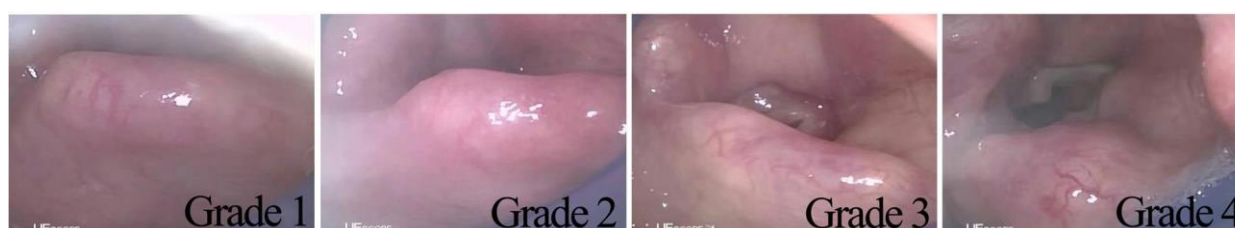

Fig. 2 SaCoVLM™ Glottic exposure grades. Grade 1: visualization of the lateral part of the right aryepiglottic fold and part of the laryngeal inlet, and the ventilation was good; Grade 2: visualization of the bilateral aryepiglottic fold and part of laryngeal inlet, and the ventilation was good; Grade 3: visualization of all laryngeal inlet and posterior glottis; Grade 4: visualization of the whole glottis

of laryngeal inlet, and the ventilation was good; Grade 3: visualization of all laryngeal inlet and partial glottis; Grade 4: visualization of the whole glottis. Fiberoptic bronchoscopy grade is as follows [7, 8]: Grade 1: visualization of no glottis; Grade 2: visualization of glottis and the lingual surface of epiglottis; Grade 3: visualization of glottis and the laryngeal surface of the epiglottis. Grade 4: visualization of glottis.

Data collection

The primary variables: visualization and grades of glottic exposure under SaCoVLM™. The secondary variables: the success rate of insertion, including the first-time success rate and the total success rate, the sealing pressure, classification under fiberoptic bronchoscopy, the insertion time, adjustment times. Other variables: intraoperative findings, secretions after SaCoVLM™ removal, soft tissue injuries (blood or bleeding), complications within postoperative 24 h (sore throat, hoarseness, difficulty swallowing).

Statistical analysis

SPSS26.0 statistical software was used. We used means and standard deviation to describe continuous data and percentages for categorical data.

Results

A total of 100 patients were recruited in this study, including 19 males (19%) and 81 females (81%), with an average age of 50.8 years, an average height of 164.1 cm and an average weight of 64.4 kg. The Demographic data are shown in Table 1.

The glottis exposure classification is showed in Table 2. All patients were observed under fiberoptic bronchoscopy to classify the glottis again.

The first-time success rate of SaCoVLM™ insertion was 95%(95% CI = 0.887 to 0.984), and the total success rate was 96%(95% CI = 0.901 to 0.989). One patient was successfully ventilated after size 4 was changed with size 3, three patients were intubated because of positive air leakage, and one patient was intubated because of excessive airway pressure. All the five patients underwent adjustments, including the up-down maneuver, raising jaw with both hands, the Chandy maneuver, increasing and reducing the amount of air, re-insertion and changing the laryngeal mask size. The average insertion time was 16.3 s. In all patients with good ventilation, the gastric tube was easy to insert. The average sealing pressure was 34.1 cmH₂O, and 72% of SaCoVLM™s achieved a sealing pressure exceeding 30 cmH₂O (Table 3).

Four cases of unsuccessful SaCoVLM™ were excluded and related complications were not followed

Table 1 Demographic data

Variables	± s/%
Gender	
Male (rate)	19 (19%)
Female (rate)	81 (81%)
Age	50.8 ± 12.2
Height (cm)	164.1 ± 7.3
Weight (kg)	64.4 ± 10.4
BMI (kg/m ²)	23.9 ± 3.0
ASA	
I	62 (62%)
II	38 (38%)
Type of operation	
Gynecological surgery	68 (68%)
General surgery	26 (26%)
Urinary surgery	6 (6%)
Pneumoperitoneum	
Yes	62 (62%)
No	38 (38%)

ASA American Society of Anesthesiologists, BMI body mass index

Table 2 Glottis exposure classification

Classification	Grade 1	Grade 2	Grade 3	Grade 4
SaCoVLM™ (cases)	55 (55%)	23 (23%)	14 (14%)	8 (8%)
Fiberoptic bronchoscopy (cases)	1 (1%)	10 (10%)	14 (14%)	71 (71%)
Adjustment of SaCoVLM™ (cases)	0 (0%)	17 (17%)	33 (33%)	50 (50%)

SaCoVLM™ classification is obtained by camera observation through the SaCoVLM™ visual channel

Grade 1: visualization of the lateral part of the right aryepiglottic fold and part of the laryngeal inlet, and the ventilation was good

Grade 2: visualization of the bilateral aryepiglottic fold and part of laryngeal inlet, and the ventilation was good

Grade 3: visualization of all laryngeal inlet and posterior glottis

Grade 4: visualization of the whole glottis

Fiberoptic bronchoscopy classification is obtained by placing the Fiberoptic bronchoscopy in the distal opening of the SaCoVLM™ vent

Grade 1: visualization of no glottis

Grade 2: visualization of glottis and the lingual surface of epiglottis;

Grade 3: visualization glottis and the laryngeal surface of the epiglottis

Grade 4: visualization of glottis

up. During the study no gastric reflux or contraposition occurred in the 96 cases that were included in the final analysis. After removal, 7% of the SaCoVLM™s were stained with blood. One case had bleeding in the mouth, and 24% had secretions near the mask sac. The incidence of postoperative sore throat was 13%, without dysphagia and hoarseness (Table 4).

Table 3 Outcomes of SaCoVLM™ insertion

Result	Cases (%)
The first-time success rate	95 (95%)(95% CI = 0.887 to 0.984)
The total success rate	96 (96%)(95% CI = 0.901 to 0.989)
SaCoVLM™ size	
size3	5 (5%)
size4	69 (69%)
size5	26 (26%)
Insertion adjustments	
Once	95 (96%)
Twice	5 (5%)
Insertion time(s)	16.3 ± 4.8
Ventilation	
Satisfaction	97 (97%)
Unable to ventilation	3 (3%)
Air leakage	
positive	3 (3%)
Negative	97 (97%)
Gastric intubation	
Positive	96 (96%)
Negative	1 (1%)
Sealing pressure (cmH ₂ O)	34.1 ± 6.2
Peak airway pressure (cmH ₂ O)	13.8 ± 3.0

Table 4 Postoperative complications

Outcomes	$\bar{x} \pm s/\%$
Gastric drainage (ml)	9.5 ± 8.5
Cuff deflating volume (ml)	31.9 ± 7.2
Blood stains	
Yes	7 (7%)
No	89 (93%)
Active bleeding in oral cavity	
Yes	1 (1%)
No	95 (99%)
Secretions	
No	73 (76%)
Yes	23 (24%)
Postoperative sore throat	
Grade 0 (none)	83 (86%)
Grade 1 (slight)	12 (12%)
Grade 3 (medium)	1 (1%)
Dysphagia	
Yes	0 (0%)
No	96 (100%)
Hoarseness	
Yes	0 (0%)
No	96 (100%)

Discussion

This SaCoVLM™ contains a camera to capture the images of the glottis and display them on a screen. We graded the images of 100 patients. Totaltrack mask can only visualize the glottis in 83% of patients [9]. LMA Ctrach, another video laryngeal mask, can expose the glottis in 85% of patients after manual adjustment [10]. Compared with the above two masks, SaCoVLM™ only visualized the glottis in eight cases after the first insertion, but in 83% patients after manual adjustment.. Only eight cases of glottis could be seen after SaCoVLM™ was placed for the first time. This was due to the insertion of the laryngeal mask using a blind insertion technique, resulting in too deep insertion of the laryngeal mask. Furthermore, the first-time success rate of SaCoVLM™ insertion was 95%, which was much higher than that of currently used LMA Supreme mask (77–88%) [11–14].

Alignment and sealing pressure are key factors that determine the effectiveness of a laryngeal mask airway. Sealing pressure can be used to identify the success of positive pressure ventilation, but also measure the airway protection [6]. We found that, after SaCoVLM™ insertion, only one case showed glottic exposure in grade 1 under fiberoptic bronchoscopy. The reason was that the epiglottis of this patient was large enough to cover the glottis. And 71 cases showed glottic exposure in grade 4, which indicated that this laryngeal mask could achieve

good alignment. Under SaCoVLM™, all the 100 patients could display their partial or whole laryngeal inlet, which lays a foundation for the in-depth study of tracheal intubation. SaCoVLM™ achieved an average sealing pressure of 34.1cmH₂O, over 30cmH₂O in 72% of patients, both much higher than those achieved by the LMA Supreme mask [15–19]. Therefore, SaCoVLM™ can serve as an effective supraglottic airway management tool.

SaCoVLM™ can monitor the conditions of and surrounding the glottis during the whole operation. Because the patients are routinely fasted and forbidden to drink before operation, gastrointestinal drainage tubes are routinely placed. With SaCoVLM™, the drainage was smooth. Muscle relaxants were added on time and body position did not changed. Therefore, we found no regurgitation of stomach contents to the larynx and glottis-SaCoVLM™ disalignment during the operation. Related complications included sore throat (13%)(slight 12%, medium 1%) [20], blood staining on SaCoVLM™ (7%), and bleeding (1%), all of which were relieved 24 h after the operation. No serious complications, such as hoarseness or dysphagia, occurred. It was found that 19.6% of the patients developed sore throat in 24 h after the use of LMA Supreme (Laryngeal mask airway supreme) and 10% showed blood stains on the laryngeal mask [18]. Other studies showed that no blood stains occurred after removing LMA Supreme, and the incidence of

sore throat was 70.6% [21]. In two studies using LMA Supreme, 7% ~ 10% of the patients presented blood stains after mask removal and 7% ~ 11.8% developed mild sore throat within 1 h after surgery [18, 22, 23]. Therefore, the incidence of complications related to SaCoVLM™ is similar to that of LMA Supreme, suggesting that it can be used safely in clinical practice.

In this study, we were unable to safely and effectively ventilate four patients with the SaCoVLM™. The airway was changed to an endotracheal tube after unsuccessful manual adjustment of the SaCoVLM™. The reasons were as follows: (1) After SaCoVLM™ insertion, the airway pressure was high to 32 cmH₂O and the perilaryngeal soft tissue obstructed ventilation; (2) Air leakage test was positive after SaCoVLM™ insertion, and the epiglottis was still reflexed after manual adjustment; (3) Air leakage test was positive after SaCoVLM™ insertion, and the patient's larynx was too high and the sealing effect of the mask was poor; (4) Size 5 was too small to match the patient who was 178 cm and 73 kg and had a large oral cavity.

In this study, the classification of SaCoVLM™ and fiberoptic bronchoscopy is quite different. The reason for the large difference is that they have different observation sites. FOB is through the laryngeal mask vent tube, and the glottis is observed at the open end of the vent tube. The SaCoVLM™ camera is located on the right side of vent cuff, which is equivalent to the right side of the vent opening end. The actual distance between the two observation sites is very small, about 0.5 cm. Although there is a great difference in the classification of glottis, there is no great difference in the actual alignment of laryngeal mask. The Table 2 shows that when the glottis can be well observed by SaCoVLM™, the alignment between LMA and glottis is very good. At the same time, it also lays a foundation for later intubation research.

Limitations also exist in this study. At present, the TotalTrack™ and LMA Ctrach™ are both video laryngeal masks, which can be used to visually guide endotracheal intubation when necessary [5, 24]. The SaCoVLM™ in this study also has the same function, but Totaltrack™ and LMA CTrach™ are not being widely used in China. Therefore, this study lacks a comparison of SaCoVLM™ with Totaltrack™ and LMA CTrach™. Second, we have mainly studied patients with Mallampati classes I-II, and this study is single center study with a relatively small sample size, therefore we are unable to determine the true effectiveness and safety of the SaCoVLM™. The reason for the small sample size is that the original purpose of this study is to be a preliminary study with a large multi-center sample size, so the sample size is small. Meanwhile all SaCoVLM™ insertions were performed by a single operator. This has the advantage of avoiding

artificial errors in glottic exposure classification and leak pressure measurements, but may lead to limitations, such as a higher success rate for SaCoVLM™ than other laryngeal masks. Finally, only 19 males were included in the study population predominantly due to most surgeries being performed in gynaecological practice. This is also a limitation of this study. However, it has been pointed out in the literature that the selection of the laryngeal mask based on weight is equally effective as that based on gender [25]. In this study, the selection was based on weight, so the gender ratio was not strictly emphasized. This observational study as a simple initial study, aiming to lay a foundation for the later multi-center large-sample study. Although the results of the preliminary study look promising, further work is required to determine whether the LMA is effective and safe for use. Multi-center and larger-sample studies involving more Mallampati III-IV and male patients are needed to verify the effectiveness and safety of SaCoVLM™.

Conclusions

In conclusion, SaCoVLM™ can visualize partial or whole laryngeal inlets during the surgery, with a high success rate, a high sealing pressure and smooth gastroesophageal drainage. SaCoVLM™ could be a promising new effective supraglottic device for airway management during general anesthesia.

Abbreviations

SaCoVLM™: SaCoVLM™ video laryngeal mask; ECG: Electrocardiogram; HR: Heart rate; BP: Blood pressure; SpO₂: Oxygen saturation; BIS: bispectral index; PETCO₂: End-tidal carbon dioxide; ASA: American Society of Anesthesiologists; BMI: Body mass index; MAP: Mean arterial pressure; LMA: Laryngeal mask airway.

Acknowledgements

Not applicable.

Authors' contributions

Z-MZ: Study design, study conduct, patient recruitment, data collection, data analysis and writing up of the first draft of the paper. Y-CL: Study design, study conduct, patient recruitment, data collection, data analysis and writing up of the first draft of the paper. CY: Study design, study conduct, patient recruitment, data collection, data analysis and writing up of the first draft of the paper. SP: Patient recruitment and data collection. Q-ZY: Data analysis. Revised and approved the final manuscript: all members of the authorship group in a supplementary file for on-line viewing only.

Funding

This research did not receive any specific grant from funding agencies in the public or commercial sectors.

Availability of data and materials

The datasets used and/or analyzed during the current study are available from the corresponding author on reasonable request.

Declarations

Ethics approval and consent to participate

This single-center prospective observational study was approved by the Ethics Committee of Clinical Research of Beijing Hospital (No. 2019BJYYEC-236-02)

and registered in the China Clinical Trial Registration Center (No. ChiCTR2000028802 Date 2020.01.04). The patients provided written consents. All methods were carried out in accordance with Declaration of Helsinki.

Consent for publication

Not Applicable.

Competing interests

The authors declare that they have no competing interests.

Author details

¹Department of Anesthesia, Beijing Hospital, National Center of Gerontology, Institute of Geriatric Medicine, Chinese Academy of Medical Sciences, Beijing, PR China. ²Peking University First Hospital, Xishiku Street, Xicheng District, Beijing, PR China.

Received: 1 April 2021 Accepted: 8 December 2021

Published online: 03 January 2022

References

- Brain AL. The laryngeal mask—a new concept in airway management. *Br J Anaesth*. 1983;55(8):801-5.
- Campbell RL, Biddle C, Assudmi N, Campbell JR, Hotchkiss M. Fiberoptic assessment of laryngeal mask airway placement: blind insertion versus direct visual epiglottoscopy. *J Oral Maxillofac Surg*. 2004;62(9):1108-13.
- Chandan SN, Sharma SM, Raveendra US, Rajendra PB. Fiberoptic assessment of laryngeal mask airway placement: a comparison of blind insertion and insertion with the use of a laryngoscope. *J Maxillofac Oral Surg*. 2009;8(2):95-8.
- Brimacombe JR. Problems with the laryngeal mask airway: prevention and management. *Int Anesthesiol Clin*. 1998;36(2):139-54.
- Liu EH, Goy RW, Chen FG. The LMA CTrach, a new laryngeal mask airway for endotracheal intubation under vision: evaluation in 100 patients. *Br J Anaesth*. 2006;96(3):396-400.
- Keller C, Brimacombe JR, Keller K, Morris R. Comparison of four methods for assessing airway sealing pressure with the laryngeal mask airway in adult patients. *Brit J Anaesth*. 1999;82(2):286-7.
- Brimacombe J, Berry A. A proposed Fiber-optic scoring system to standardize the assessment of laryngeal mask airway position. *Anesth Analg*. 1993;76(2):457.
- Kim GW, Kim JY, Kim SJ, Moon YR, Park EJ, Park SY. Conditions for laryngeal mask airway placement in terms of oropharyngeal leak pressure: a comparison between blind insertion and laryngoscope-guided insertion. *BMC Anesthesiol*. 2019;19(1):4.
- Gomez-Rios MA, Freire-Vila E, Casans-Frances R, Pita-Fernandez S. The Totaltrack (TM) video laryngeal mask: an evaluation in 300 patients. *Anaesthesia*. 2019;74(6):751-7.
- Timmermann A, Russo S, Graf BM. Evaluation of the CTrach—an intubating LMA with integrated fibreoptic system. *Br J Anaesth*. 2006;96(4):516-21.
- Eschertzhuber S, Brimacombe J, Hohlrieder M, Keller C. The laryngeal mask airway Supreme—a single use laryngeal mask airway with an oesophageal vent. A randomised, cross-over study with the laryngeal mask airway ProSeal in paralysed, anaesthetised patients. *Anaesthesia*. 2009;64(1):79-83.
- Mukadder S, Zekine B, Erdogan KG, Ulku O, Muharrem U, Saim Y, et al. Comparison of the proseal, supreme, and i-gel SAD in gynecological laparoscopic surgeries. *ScientificWorldJournal*. 2015;2015:634320.
- Kriege M, Piepho T, Zanker S, Afflen C, Heid F, Noppens FR. LMA supreme (TM) and Ambu((R)) AuraGain (TM) in anesthetized adult patients: a prospective observational study. *Minerva Anesthesiol*. 2017;83(2):165-74.
- Chaw SH, Shariffuddin II, Foo LL, Lee PK, Paran RM, Cheang PC, et al. Comparison of clinical performance of size 1.5 supreme LMA and ProSeal LMA among Asian children: a randomized controlled trial. *J Clin Monit Comput*. 2018;32(6):1093-9.
- Shariffuddin II, Teoh WH, Tang EBK, Hashim NHM, Loh PS. Ambu (R) AuraGain (TM) versus LMA supreme (TM) second seal (TM): a randomised controlled trial comparing oropharyngeal leak pressures and gastric drain

functionality in spontaneously breathing patients. *Anaesth Intensive Care*. 2017;45(2):244-50.

- Wong DT, Yang JJ, Jagannathan N. Brief review: the LMA supreme supra-glottic airway. *Can J Anaesth*. 2012;59(5):483-93.
- Somri M, Vaida S, Garcia Fomari G, Mendoza CR, Charco-Mora P, Hawash N, et al. A randomized prospective controlled trial comparing the laryngeal tube suction disposable and the supreme laryngeal mask airway: the influence of head and neck position on oropharyngeal seal pressure. *BMC Anesthesiol*. 2016;16(1):87.2.
- Seet E, Rajeev S, Firoz T, Yousaf F, Wong J, Wong DT, et al. Safety and efficacy of laryngeal mask airway supreme versus laryngeal mask airway ProSeal: a randomized controlled trial. *Eur J Anaesthesiol*. 2010;27(7):602-7.
- Park JY, Yu J, Hong JH, Hwang JH, Kim YK. Head elevation and laryngeal mask airway Supreme insertion: a randomized controlled trial. *Acta Anaesthesiol Scand*. 2021;65(3):343-50.
- Evans NR, Gardner SV, James MF, King JA, Roux P, Bennett P, et al. The proseal laryngeal mask: results of a descriptive trial with experience of 300 cases. *Br J Anaesth*. 2002;88(4):534-9.
- Komur E, Bakan N, Tomruk SG, Karaoren G, Dogan ZT. Comparison of the Supraglottic airway devices classic, Fastrach and supreme laryngeal mask airway: a prospective randomised clinical trial of efficacy. Safety and Complications *Turk J Anaesthesiol*. 2015;43(6):406-11.
- Tan BH, Chen FG, Liu EHC. An evaluation of the laryngeal mask airway supreme™ in 100 patients. *Anaesth Intensive Care*. 2010;38(3):550-4.
- Lopez AM, Valero R, Brimacombe J. Insertion and use of the LMA supreme in the prone position. *Anaesthesia*. 2010;65(2):154-7.
- Gomez-Rios MA, Freire-Vila E, Vizcaino-Martinez L, Estevez-Gonzalez E. The Totaltrack: an initial evaluation. *Br J Anaesth*. 2015;115(5):799-800.
- Kihara S, Joseph R B, Yaguchi Y, Taguchi N, Watanabe S. A comparison of sex- and weight-based ProSeal™ laryngeal mask size selection criteria: a randomized study of healthy anesthetized, paralyzed adult patients. *Anesthesiology*. 2004;101(2):340-3.

Publisher's Note

Springer Nature remains neutral with regard to jurisdictional claims in published maps and institutional affiliations.

Ready to submit your research? Choose BMC and benefit from:

- fast, convenient online submission
- thorough peer review by experienced researchers in your field
- rapid publication on acceptance
- support for research data, including large and complex data types
- gold Open Access which fosters wider collaboration and increased citations
- maximum visibility for your research: over 100M website views per year

At BMC, research is always in progress.

Learn more biomedcentral.com/submissions

